

**RETINAL FRACTAL DIMENSION ANALYSIS AT  
OPTIC NERVE HEAD USING SMARTPHONE-  
ASSISTED FUNDUS PHOTOGRAPHY ON EYES WITH  
DIABETES MELLITUS RISK FACTORS**

**BY**

**NUR RAIHAN BINTI ESA**

A thesis submitted in fulfilment of the requirement for the  
degree of Master of Health Sciences (Optometry)

**Kulliyyah of Allied Health Sciences  
International Islamic University Malaysia**

**NOVEMBER 2020**

## ABSTRACT

Fractal dimension (Df) analysis have been shown as a sensitive measure for charting retinal vascular changes, while smartphone-assisted fundus photography (SAFP) has been demonstrated as a useful tool in screening eyes with problem related to diabetes mellitus (DM). We took these two tools together to investigate the DM risk factors using the best chosen SAFP by measuring the Df. The objectives of this thesis were: (i) to determine the best retinal image of two SAFPs, the Peek Retina™ and 3DPO for Df analysis; (ii) to assess the reliability of Df analysis using the chosen best SAFP; (iii) and to compare the Df of the optic nerve head (ONH) vasculatures between groups with risk- and non-risk of DM: and (iv) to explore the potential association of ONH vasculature's Df with risk factors of DM. For the first objective, our first experiment compared the retinal images between Peek Retina™ and 3DPO. It was determined that PEEK Retina™ was preferred for retinal vascular tracing work for Df analysis, in comparison to 3DPO. In experiment two, based on the best SAFP in the first experiment finding, we determined the Df analysis reliability using the images taken using Peek Retina™. It was shown that the intragrader and intergraders reliabilities were both in good agreement. Peek Retina™ has shown as a reliable SAFP to evaluate retinal vasculature using Df analysis. For objectives three and four, the ONH vasculatures Df value were analysed in groups with risk and non-risk of DM. The results indicated that the ONH vasculatures Df value was not significantly different between the groups, and there was no associations observed between ONH vasculature Df with DM risk factors. The findings in this thesis advocated that the Peek Retina™ is a reliable tool for the evaluation of retinal vascular Df and may be used in expansion of ophthalmic services in various setting. The result in this study also confirms that changes that due to DM probably occurs in the peripheral vessels, and ONH Df values was not associated with DM risk factors.

## خلاصة البحث

في هذا البحث تم إثبات البعد الكسري (Df) كقياس حساس لرسم مخطط تغيرات الأوعية الدموية في شبكية العين، وأيضاً تم إثبات تصوير قاع العين بمساعدة الهاتف الذكي (SAFP) كأداة مفيدة في فحص العيون التي تعاني من مشاكل تتعلق بداء السكري (DM). لقد استخدمنا هاتين الأداةين معاً للتحقق من عوامل الخطورة للإصابة بداء السكري باستخدام أفضل أداة لتصوير قاع العين بمساعدة الهاتف الذكي من خلال قياس البعد الكسري. كانت أهداف هذه الأطروحة: (1) تحديد أفضل صورة لشبكية العين لاثنتين من أفضل أدوات تصوير لقاع العين المأخوذة بمساعدة الهاتف الذكي، وهما Peek Retina™ و 3DPO بهدف تحليل الأبعاد الكسرية؛ (2) تقييم موثوقية تحليل البعد الكسري باستخدام أفضل أداة مختارة لتصوير قاع العين بمساعدة الهاتف الذكي؛ (3) ومقارنة البعد الكسري لأوعية رأس العصب البصري (ONH) بين المجموعات المعرضة وغير المعرضة لخطر الإصابة بداء السكري؛ و(4) استكشاف الصلة المحتملة بين البعد الكسري لأوعية رأس العصب البصري وعوامل خطر الإصابة بمرض السكري. بالنسبة للهدف الأول، قارنت تجربتنا الأولى صور شبكية العين المأخوذة ب Peek Retina™ و DPO3. تبين أن Peek Retina™ كانت مفضلة لتتبع الأوعية الدموية في شبكية العين لتحليل البعد الكسري، مقارنةً بـ DPO3. في التجربة الثانية، واستناداً إلى أفضل أداة لتصوير لقاع العين بمساعدة الهاتف الذكي والتي حددت في التجربة الأولى، حددنا موثوقية تحليل البعد الكسري باستخدام الصور الملتقطة باستخدام Peek Retina™. لقد تبين أن موثوقية intragrader و intergraders كانت على اتفاق جيد. تبين أن Peek Retina™ قد أظهرت تصويراً موثقاً لقاع العين بمساعدة الهاتف الذكي من أجل تقييم الأوعية الدموية في شبكية العين من خلال تحليل الأبعاد الكسرية. بالنسبة للهدفين الثالث والرابع، تم تحليل قيمة البعد الكسري لأوعية العصب البصري في المجموعات المعرضة وغير المعرضة لخطر الإصابة بداء السكري. أشارت النتائج إلى أن قيمة البعد الكسري لأوعية العصب البصري لم تختلف بشكل كبير بين المجموعات، ولم يلاحظ وجود ارتباطات بين البعد الكسري لأوعية رأس العصب البصري مع عوامل خطورة الإصابة بداء السكري. دعت النتائج في هذه الرسالة إلى أن Peek Retina™ هي أداة موثوقة لتقييم البعد الكسري للأوعية الدموية في شبكية العين ويمكن استخدامها في توسيع خدمات طب العيون في مواضع مختلفة. تؤكد نتيجة هذه الدراسة أيضاً أن التغيرات التي تحدث بسبب داء السكري ربما تحدث في الأوعية المحيطية، وأن قيم البعد الكسري لرأس العصب البصري لم ترتبط بعوامل خطورة للإصابة بمرض السكري.

## APPROVAL PAGE

I certify that I have supervised and read this study and that in my opinion, it conforms to acceptable standards of scholarly presentation and is fully adequate, in scope and quality, as a thesis for the degree of Master of Health Sciences (Optometry).

.....  
Asst. Prof. Dr. Firdaus Yusof @  
Alias  
Supervisor

.....  
Asst. Prof. Dr. Nor Azwani Mohd  
Shukri  
Co-Supervisor

.....  
Assoc. Prof. Dr. Mohd Zulfaezal  
Che Azemin  
Co-Supervisor

.....  
Asst. Prof. Dr. Norsham Ahmad  
Co-Supervisor

I certify that I have read this study and that in my opinion it conforms to acceptable standards of scholarly presentation and is fully adequate, in scope and quality, as a thesis for the degree of Master of Health Sciences (Optometry).

.....  
Dr. Saadah Mohamed Akhir  
Internal Examiner


.....  
Asst. Prof. Dr. Afzam Shah  
Abdul Rahim  
External Examiner

This thesis was submitted to the Department of Optometry and Visual Science and is accepted as a fulfilment of the requirement for the degree of Master of Health Sciences (Optometry).

.....  
Asst. Prof. Dr. Norsham Ahmad  
Head, Department of Optometry  
and Visual Science

This thesis was submitted to the Kulliyah of Allied Health Sciences and is accepted as a fulfilment of the requirement for the degree of Master of Health Sciences (Optometry).

.....  
Prof. Dr. Suzanah Abdul Rahman  
Dean, Kulliyah of Allied Health  
Sciences

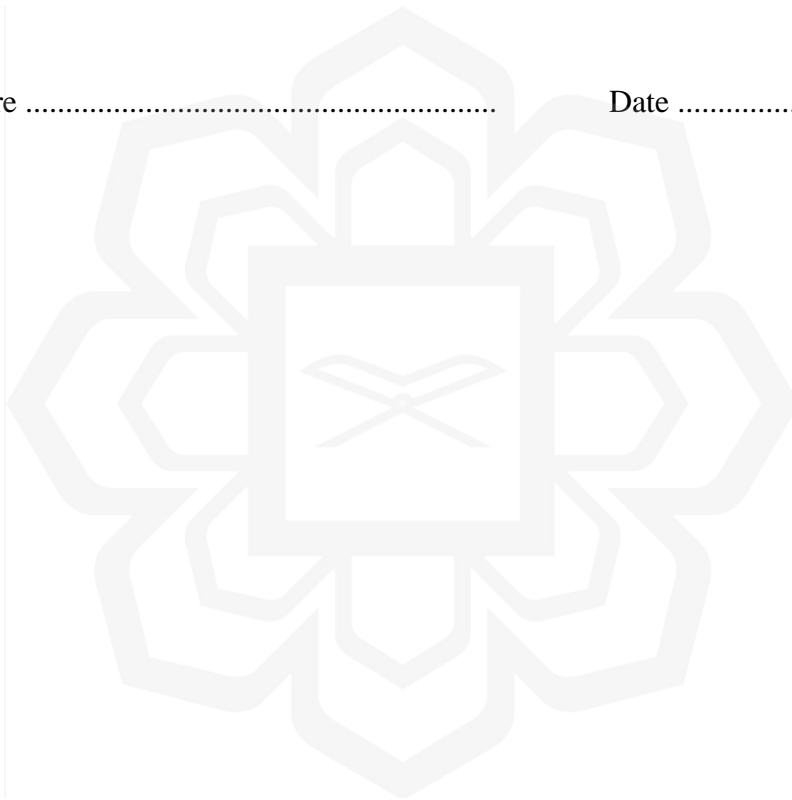


## DECLARATION

I hereby declare that this dissertation is the result of my own investigations, except where otherwise stated. I also declare that it has not been previously or concurrently submitted as a whole for any other degrees at IIUM or other institutions.

Nur Raihan binti Esa

Signature ..... Date .....



**INTERNATIONAL ISLAMIC UNIVERSITY MALAYSIA**

**INTERNATIONAL ISLAMIC UNIVERSITY MALAYSIA  
DECLARATION OF COPYRIGHT AND AFFIRMATION OF  
FAIR USE OF UNPUBLISHED RESEARCH**

**RETINAL FRACTAL DIMENSION ANALYSIS USING  
SMARTPHONE-ASSISTED FUNDUS PHOTOGRAPHY ON  
EYES WITH DIABETES MELLITUS RISK FACTORS**

I declare that the copyright holders of this dissertation are jointly owned by the student and IIUM.

Copyright ©2020 Nur Raihan binti Esa and International Islamic University Malaysia. All rights reserved.

No part of this unpublished research may be reproduced, stored in a retrieval system, or transmitted, in any form or by any means, electronic, mechanical, photocopying, recording or otherwise without prior written permission of the copyright holder except as provided below

1. Any material contained in or derived from this unpublished research may be used by others in their writing with due acknowledgement.
2. IIUM or its library will have the right to make and transmit copies (print or electronic) for institutional and academic purposes.
3. The IIUM library will have the right to make, store in a retrieved system and supply copies of this unpublished research if requested by other universities and research libraries.

By signing this form, I acknowledged that I have read and understand the IIUM Intellectual Property Right and Commercialization policy.

Affirmed by Nur Raihan binti Esa

.....  
Signature

.....  
Date

## ACKNOWLEDGEMENTS

Alhamdulillah, I offer my sincerest gratitude to Allah for giving me the *hidayah*, spirit and patience to complete this thesis. For without Him, I will be the weakest person in this world.

First, my special and heartily thanks to my supervisors Dr. Firdaus, Dr. Azwani, Dr Zulfaezal and Dr Norsham for their guidance, advice, valuable comments, suggestions and provisions that benefited me much for the development of this thesis content. Their encouragement and inspiring motivations have been precious in the completion and success of my thesis.

My deepest thanks to my beloved friends Nura Syahiera, Fatin Amalina and Nur Amani Izzati who have stayed by me throughout this research. They were fundamental in supporting me during these stressful and difficult moments.

I wish to express my appreciation and thanks to all the lectures and staff of Postgraduate and Research Office and DOVS for your time, effort and support for this project.

Finally, it is my utmost pleasure to dedicate this work to my dear parents, Esa bin Abd Rahman and Aribah binti Ahmad and my family, who granted me the gift of their unwavering belief in my ability to accomplish this goal: thank you for your endless prayers and support for my success in this life.

# TABLE OF CONTENTS

Abstract .....	ii
خلاصة البحث .....	iii
Approval Page.....	ii
Declaration .....	iv
Copyright .....	v
Acknowledgements .....	vi
Table of contents .....	vii
List of Tables .....	xi
List of Figures .....	xii
List of Abbreviations .....	xiv
<b>CHAPTER ONE: INTRODUCTION.....</b>	<b>1</b>
1.1 Background of The Study .....	1
1.2 Rationale And Hypothesis Of The Study .....	2
1.3 Organization Of The Thesis.....	7
<b>CHAPTER TWO: LITERATURE REVIEW .....</b>	<b>9</b>
2.1 Anatomy of Retinal Vessels Network .....	9
2.2 Diabetes Mellitus (DM).....	11
2.2.1 T2DM Risk Factors.....	13
2.2.1.1 Age .....	13
2.2.1.2 Sex .....	14
2.2.1.3 Genetic.....	14
2.2.1.4 History of GDM .....	15
2.2.1.5 Hypertension.....	16
2.2.1.6 Obesity.....	16
2.3 DM and its Effect to End Organs .....	17
2.4 Fundus Imaging .....	18
2.5 Portable Fundus Imaging and SAFP methodologies .....	20
2.6 Fractal dimension (Df).....	25
2.6.1 Factors Affecting Retinal Vascular Df Measurement.....	27
<b>CHAPTER THREE: METHODOLOGY .....</b>	<b>30</b>
3.1 Location of the study .....	30
3.2 Research Design and Sampling Method.....	30
3.3 Participants Recruitment.....	30
3.4 Research Tools.....	32
3.4.1 Slit Lamp SL-203 (SHIN-NIPPON, Rexam Co., Ltd, Japan) .....	32

3.4.2 Pulsair IntelliPuff Non-contact tonometer (SL4 4AA, Keeler Ltd, Uk)	33
3.4.3 Modified adjustable joystick desk.....	33
3.4.4 Smartphone Samsung SM-G925F (Samsung C&T Corp., Seoul, Republic of Korea).....	35
3.4.5 Smartphone-Assisted Fundus Photography (SAFP) devices .....	35
3.4.5.1 Portable eye examination kit (Peek Retina™, Peek Vision Ltd, UK).....	36
3.4.5.2 3D Printed Ophthalmoscope (3DPO).....	37
3.4.6 Samsung Galaxy Tab A 8.0 SM-P355 (Samsung C&T Corp., Seoul, Republic of Korea).....	38
3.4.7 Anthropometric measuring tools.....	39
3.4.7.1 Digital weighing scale (HD 382®, Tanita, USA) .....	39
3.4.7.2 Stadiometer Height-Rod (Seca 213, Seca GmbH & Co. Kg, Germany).....	39
3.4.7.3 Blood Pressure Monitor (HEM-907, OMRON, Japan).....	39
3.5 Materials .....	40
3.5.1 Ophthalmic drugs .....	40
3.5.2 GNU Image Manipulation Program (GIMP) Version 2.8.18 .....	40
3.5.3 Retinal Image Quality Assessment (RIQA).....	40
3.5.4 SketchBook for Galaxy Apps version 3.2.0 (Autodesk, Inc.®, Seoul and Republic of Korea) .....	41
3.5.5 Image J Software and FracLac .....	42
3.5.6 International Physical Activity Questionnaire – Short (IPAQ-S) ....	43
3.5.7 Nutritionist Pro™ Version 4.0.0 (Axxya System, USA) .....	43
3.6 Study Flow.....	44
3.7 Statistical analysis.....	47

**CHAPTER FOUR: RETINAL IMAGE QUALITY ASSESSMENT: PORTABLE EYE EXAMINATION KIT RETINA (PEEK RETINA™) VERSUS 3D PRINTED OPHTHALMOSCOPE (3DPO) ..... 48**

Abstract.....	49
4.1 Introduction.....	50
4.2 Material And Methods.....	52
4.2.1 Study Population .....	52
4.2.2 Smartphone-Assisted Fundus Photography .....	53
4.2.3 Retinal Image Photograph.....	54
4.2.4 Retinal Image Quality Assessment (RIQA).....	56
4.2.5 Statistical Analysis .....	57
4.3 Result .....	58
4.4 Discussion.....	60

**CHAPTER FIVE: RELIABILITY OF MANUAL VASCULAR SEGMENTATION FOR RETINAL FRACTAL DIMENSION USING PORTABLE EYE EXAMINATION KIT RETINA (PEEK RETINA™) ..... 64**

Abstract .....	65
5.1 Introduction.....	66
5.2 Methodology.....	68
5.2.1 Study Population .....	68
5.2.2 Retinal Photograph and Image Analysis.....	69
5.2.3 Measurement of Df .....	71
5.2.4 Reliability Analysis Procedures .....	72
5.2.5 Statistical Analysis.....	72
5.3 Result .....	73
5.4 Discussion.....	75

**CHAPTER SIX: AN EXPLORATORY STUDY: RETINAL VASCULAR FRACTAL DIMENSION AND ITS ASSOCIATION WITH DIABETES MELLITUS RISK FACTORS..... 79**

Abstract .....	80
6.1 Introduction.....	81
6.2 Methodology.....	82
6.2.1 Study Population .....	82
6.2.2 Sample Size Calculation .....	83
6.2.3 Retinal Image Photography and Image Analysis.....	84
6.2.4 Measurement of Df .....	84
6.2.5 Anthropometry measurements .....	84
6.2.6 Blood pressure measurement .....	85
6.2.7 Assessment of dietary intake.....	85
6.2.8 Physical activity evaluation.....	86
6.2.9 Statistical Analyses .....	87
6.3 Results .....	87
6.3.1 Descriptive analysis .....	87
6.3.2 Comparison of retinal Df values between groups with and without risk of DM.....	89
6.3.3 Potential association between retinal Df values and DM risk factors .....	90
6.4 Discussion.....	91
6.4.1 Retinal Df values and risk of DM .....	91
6.4.2 Association between retinal Df value and DM risk factors .....	94

**CHAPTER SEVEN: GENERAL DISCUSSION..... 99**

7.1 Research Strength and Limitation .....	101
7.2 Recommendations for future work .....	102
7.3 Summary.....	103

<b>REFERENCES.....</b>	<b>105</b>
<b>APPENDIX I: CONSENT FORM.....</b>	<b>124</b>
<b>APPENDIX II: DIABETES RISK TEST QUESTIONNAIRE .....</b>	<b>126</b>
<b>APPENDIX III: ETHICAL APPROVAL .....</b>	<b>129</b>
<b>APPENDIX IV: RETINAL IMAGE QUALITY ASSESSMENT.....</b>	<b>131</b>
<b>APPENDIX V: INTERNATIONAL PHYSICAL ACTIVITY QUESTIONNAIRE- SHORT (IPAQ-S) .....</b>	<b>136</b>
<b>APPENDIX VI: RELATED PUBLICATIONS .....</b>	<b>143</b>
<b>APPENDIX VII: COPYRIGHT AND PERMISSION.....</b>	<b>145</b>
<b>APPENDIX VIII: CONFERENCE.....</b>	<b>147</b>



## LIST OF TABLES

<u>Table No.</u>		<u>Page No.</u>
Table 1.1	Summarization of the objectives and hypotheses of the study.	7
Table 2.1	Characteristics of film-based imaging and digital fundus imaging.	19
Table 2.2	Characteristics of Direct and Indirect SAFP devices.	22
Table 2.3	Summary of findings relating to validity and reliability of SAFP devices.	24
Table 3.1	Specifications of Samsung Galaxy Tab A 8.0 SM-P355 (Samsung C&T Corp., Seoul, Republic of Korea).	38
Table 4.1	Participants' demographics information (n=20).	58
Table 4.2	Comparison of blood vessel tracing preference scales between Peek Retina™ (n=200) and 3DPO (n=200).	60
Table 5.1	Reliability estimate of intragrader and intergrader for Df measurements.	74
Table 5.2	Bland Altman analysis of intragrader and intergrader for Df measurements.	75
Table 6.1	Classification of BMI adopted from WHO (1998).	84
Table 6.2	Blood pressure category based on AHA (Whelton et al., 2017)	85
Table 6.3	Characteristics of participants in non-risk and risk group of DM.	88
Table 6.4	Comparison of retinal vascular Df between non-risk and risk group of DM (n=90).	89
Table 6.5	Relationship of DM risk factors with retinal vascular Df.	90

## LIST OF FIGURES

<u>Figure No.</u>		<u>Page No.</u>
Figure 2.1	Schematic diagram of self-similar structure, the small magnified structure resembles the largest form (Goldberger, 1996) <i>Image reproduced with permission from The Lancet.</i>	26
Figure 2.2	Different box sizes covering the images of interest and the boxes that contained pixels are counted.	27
Figure 3.1	A cylindrical Styrofoam with a phone holder was placed on top of the base of modified desk with adjustable joystick.	33
Figure 3.2	Smartphone attached with Peek Retina™ was fastened in the phone holder on the Styrofoam base.	34
Figure 3.3	The 3DPO with +20D auxiliary lens and smartphone was placed on top of the cylindrical Styrofoam. This adapter and phone tool was moved accordingly on the Styrofoam base to take picture.	34
Figure 3.4	A) Peek Retina™ B) 3DPO.	35
Figure 3.5	Optical principle of a direct ophthalmoscope.	36
Figure 3.6	A) Optical principle of indirect ophthalmoscope. B) Optical principle of 3DPO; observer's eye is replaced by smartphone to perceive the image (Nazari Khanamiri, Nakatsuka, & El-Annan, 2017). <i>Image reproduced with permission from Journal of Visualized Experiments.</i>	37
Figure 3.7	Graphic tool icons of Autodesk SketchBook Pro for Galaxy software.	42
Figure 3.8	Flow of the study Experiment 1. The detail explanation of the method is elaborated in Chapter Four of this thesis.	45
Figure 3.9	Flow of the study Experiment 2. The detail explanation of the method is elaborated in Chapter Five of this thesis.	46
Figure 3.10	Flow of the study Experiment 3. The detail explanation of the method is elaborated in Chapter Six of this thesis.	47
Figure 4.1	The good focus of retinal image with visible ONH blood vessels of a 27 years old Malay female captured by Peek Retina™.	55


<u>Figure No.</u>		<u>Page No.</u>
Figure 4.2	The retinal image of 22 years old Malay male captured by 3DPO.	56
Figure 4.3	A) The region of interest was selected and cropped approximately following the size and shape of the cornea. B) The cropped image was resized to the standard size of 900 by 900 of resolution.	57
Figure 4.4	Bar graph of blood vessel tracing difficulty level between two types of portable fundus cameras.	59
Figure 5.1	A decentered optic nerve head of retinal image which obstructed the appearance of retinal vasculature in the lower retinal fundus region.	70
Figure 5.2	A good visibility of retinal blood vessels.	70
Figure 5.3	A) The ROI (0.5 disc diameter) cropped retinal image; B) A binary image of self-skeleton line tracing of retinal blood vessels branching pattern.	72
Figure 5.4	Limit of Agreement (LoA) of intragrader agreement for retinal Df.	74
Figure 5.5	Limit of Agreement (LoA) of intergrader agreement for retinal Df.	75
Figure 6.1	Retinal image of a 45-year old healthy individual captured by a standard fundus camera, Topcon TRC-NW6S (Topcon, Tokyo, Japan).	92

## LIST OF ABBREVIATIONS

AHA	American Heart Association
AI	Artificial intelligence
ANCOVA	Analysis of covariance
BC	Box counting
BMI	Body mass index
BP	Blood pressure
Bpm	Beats per minute
CI	Confidence interval
cm	Centimeter
CRA	Central retinal artery
DS	Diopter Sphere
DBP	Diastolic blood pressure
Df	Fractal dimension
DM	Diabetes mellitus
DR	Diabetic retinopathy
DRTQ	Diabetes Risk Test Questionnaire
e.g.	for example
et.al.	<i>(et alia)</i> ; and others
FOP	Fundus on Phone
FOV	Field of view
G	Gram
GDM	Gestational diabetes mellitus
GIMP	Gnu Image Manipulation Program
i.e.	that is
ICC	Intraclass Correlation Coefficient
ICT	Information and communication technologies
IGT	Impaired glucose tolerance

IIUM	International Islamic University Malaysia
IOP	Intraocular pressure
iOS	iPhone operating system
IPAQ-S	International Physical Activity Questionnaires-Short
IPL	inner plexiform layer
IREC	IIUM Research Ethics Committee
IRMA	Intraretinal microvascular abnormalities
k	Kappa
kcal	Kilocalorie
kg	Kilogram
L	Side length
LCD	Liquid-crystal display
LED	Light emitting diode
LoA	Limit of Agreement
m	Meter
mm	Millimeter
mmHg	Millimeter mercury
MAP	Mean arterial pressure
MET	resting metabolic rate
NDR	National Diabetes Registry
NIH	National Institute of Health
ONH	Optic nerve head
RE	Refractive error
RIQA	Retinal Image Quality Assessment
RNFL	retinal nerve fiber layer
ROI	Region of interest
SAFP	Smartphone-assisted Fundus Photography
SBP	Systolic Blood Pressure
SD	Standard Deviation

SPSS	Statistical Package for the Social Science
T1DM	Type 2 diabetes mellitus
T2DM	Type 2 diabetes mellitus
TFT	Thin-film-transistor
μm	Micrometer
VGEF	vascular endothelial growth factors
WHO	World Health Organization
2D	Two-dimensional
3D	Three-dimensional
3DPO	3D Printed Ophthalmoscope



# **CHAPTER ONE**

## **INTRODUCTION**

The advancement of technology give rise to the development of smartphone-assisted fundus photography (SAFP). SAFP gives access to a portable, rapid, and cheap digital fundus imaging technique for assessing retinal conditions. Digital fundus imaging is useful in many aspects especially in the study of vascular network geometrical patterns for detection of retinal pathologies. Early detection of ocular diseases such as diabetic retinopathy (DR), by means of measuring the vascularity profiles, in return will reduce the risk for visual impairment or blindness.

### **1.1 BACKGROUND OF THE STUDY**

Visual impairment and blindness are serious public health issues worldwide affecting 2.2 billion people (WHO, 2019). It is interesting to note that the number of people affected by visual impairment and blindness due to preventable and treatable causes has decrease from 81.7% in 2010 to 80.8% by 2020 (Bourne et al., 2017; Flaxman et al., 2017). Nevertheless, visual problem due to non-communicable diseases such as DR showed a progressive increment in years to come (Flaxman et al., 2017). Visual impairment and blindness attributed to DR is expected to rise to 3.2 million by year 2020, relative to its lower prevalence of 1.6 million in 1990 (Flaxman et al., 2017).

DR is the most common microvascular complication of diabetes mellitus (DM). Data in 2010 demonstrated that 95 million people, among 285 million people with DM, have signs of DR or vision-threatening DR (Yau et al., 2012). Cases involving undiagnosed DM has shown to increase the risk for the development of DR and other

microvascular complications (e.g. nephropathy and neuropathy) due to prolonged untreated or prolonged uncontrolled high blood glucose level (Chawla, Chawla, & Jaggi, 2016). Increasing number of DM cases which include both diagnosed and undiagnosed diabetes are possibly the major cause of the increment in the prevalence of DR. Detection of DM at earlier stage is logically an important step in preventing diabetic-related visual complications.

Early screening of ocular fundus is an important step for managing, and to a larger extent, for preventing DR (Ting, Cheung, & Wong, 2016). The standard tabletop fundus camera was deliberated as the main diagnostic tool in the evaluation of retina due to its capability to produce high-quality image. However, the disadvantages of tabletop fundus camera which include being bulky, expensive, office-based setting and technician dependent characteristics may restrict its usability for screening. The introduction of SAFF is an ideal alternative for screening as this tool being portable, ubiquitous, low cost and has wireless transmission ability (DeBuc, 2016; Micheletti, Hendrick, Khan, Ziemer, & Pasquel, 2016). Retinal images obtained using SAFF may be utilized in retinal vasculatures and morphology analysis which in return may aid for the detection of pathologies at an earlier stage.

## **1.2 RATIONALE AND HYPOTHESIS OF THE STUDY**

Taking advantage of the widespread use of smartphones, SAFF provides an opportunity to be used in screening and monitoring of retinal pathologies including DR. Most studies reported that images taken using SAFF devices have sufficient quality relative to those taken using standard fundus camera (Ludwig, Shan, et al., 2016; Panwar et al., 2016). SAFF device such as the Portable Eye Examination Kit Retina (Peek Retina™, Peek Vision Ltd, England, UK) has good agreement with the standard fundus camera

in assessing optic nerve head (ONH) as reported by Bastawrous et al. (2016), in their Nakuru Eye Disease Project in Kenya. Other devices such as 3D Printed Ophthalmoscope (3DPO) was ascertained to produce satisfactory fundus photo quality for normal or pathological retinal status with high resolution (Hong, 2015; Myung, Jais, He, Blumenkranz, & Chang, 2014). Combining SAFF capabilities together with the sophistication of image processing such as fractal dimension (Df) analysis, retinal images from SAFF may be used for quantitative analysis. Df is an indirect measure of vascular complexity (Karperian, 2013), turning a qualitative nature such that of retinal vascularity, into a numerical value of quantitative measure. Having a higher Df value may indicate a more complex vascularity while low Df value may indicate less visible blood vessels. All studies in the past pertaining to Df have used retinal images from the standard fundus camera (Ab Hamid et al., 2016; Azemin et al., 2011; F. Huang et al., 2015; MacGillivray, Patton, Doubal, Graham, & Wardlaw, 2007). Retinal images taken using SAFF has yet been reported of used in Df analysis. In addition, the quality of images between SAFF devices, in terms of blood vasculatures visibility has yet to be explored. Thus, the objectives in this research project were to answer these questions, if not partly to answer their predicaments.

In the first experiment in this thesis we aimed to decide the best SAFF device between the Peek Retina™ and 3DPO, for producing quality retinal image.

- Objective 1: To compare the quality of retinal image based on preferences scale of blood vasculature tracing between two SAFF devices namely Peek Retina™ and 3DPO.
- Research hypothesis: Peek Retina™ was expected to have better retinal image quality in term of blood vessels visibility compared to 3DPO.

In experiment 1, Peek Retina™ was established as a device that able to capture retinal images with a significant blood vessels visibility compared to 3DPO.

Many studies in analyzing retinal vascular Df have used retinal images with high resolution and large field of view (FOV), which usually captured by diagnostic fundus camera (Ab Hamid et al., 2016; Cheung et al., 2012; Corvi et al., 2018; Liew, Wang, Cheung, et al., 2008; McGowan et al., 2015). Fundus camera provides images with good quality and large FOV which allows blood vessels to be self-segmented by using computer assisted segmentation process. Nevertheless, images captured by SAFFP may require manual segmentation for vascular tracing, due to its smaller FOV. It is thus imperative to analyze the reliability of the manual vascular segmentation using images from SAFFP for the Df analysis. We have established in Experiment 1 that Peek Retina™ as the better SAFFP device in terms of producing images that are better for vascular tracing process, hence Experiment 2 will utilize images from this device. Thus, the objective placed for the second experiment was as follows;

- Objective 2: To assess the intragrader and intergrader reliability of manual vasculature segmentation method using retinal image photographed by Peek Retina™ for retinal Df analysis.
- Research hypothesis: Images captured by Peek Retina™ has good reliability in the manual vascular segmentation for the Df analysis.

In experiment 2, it was established that manual vascular segmentation using retinal images from Peek Retina™ has shown good reliability for Df analysis.

In the third experiment, we want to test the applicability of SAFFP on groups with DM risk factors by using Df analysis. Numerous studies have shown that the retinal vascular complex among DM population, using images from standard tabletop fundus

camera, were different relative to the healthy eyes (Aliahmad, Kumar, Sarossy, & Jain, 2014; Cheng & Huang, 2003; Cheung et al., 2012; Cheung et al., 2009; Leontidis, Al-diri, & Hunter, 2015; Popovic, Radunovic, Badnjar, & Popovic, 2018; Yau et al., 2010). A few studies showed of a significantly lower retinal Df values in population with DM (Cheung et al., 2012; Leontidis, Al-diri, Wigdahl, & Hunter, 2015; Popovic et al., 2018). In contrast, some studies demonstrated the retinal Df values as higher in population with DM, with increasing vascular complexity following DM severity (Aliahmad, Kumar, Sarossy, et al., 2014; Yau et al., 2010). Evidence of higher complexity of retinal vascular has been shown in DM patients with proliferative DR due to presence of neovascularization (Cheng & Huang, 2003). Those studies on retinal vasculatures Df showed changes in vascular complexity particularly on the macula. However, DM also caused damage to the peripheral retinal area including neuroretinal system. Studies showed that the progression of diabetes would altered the metabolic and hemodynamic process, which lead to destruction of optic nerve (Barber et al., 1998; Barber, Gardner, & Abcouwer, 2011). Metabolically, persistent hyperglycemia impaired both retinal vessels and retinal neurons in ONH by apoptosis of retinal ganglion cells (RGC; degeneration process; Barber et al., 2011; Victor, 2018). Long-term damage of RGC resulted in abnormal capillary permeability and damage of capillary cells which progressively diminishing the retinal nerve fibre layer (Araszkievicz et al., 2012; Dijk et al., 2012). Other than that, high blood sugar level also caused the reduction of oxygen total in blood (hypoxia) within adipose tissues of ONH retinal vasculatures (Foti & Brunetti, 2017). Hypoxic condition in vessel tissues stimulated the angiogenesis process, thus lead to neovascularization in optic disc (NVD; Corvera & Gealekman, 2014). These mechanisms promoted the changes in both functional and structural of the ONH vessels leading to the alteration of retinal vascular complexity. The subtle changes

of retinal vessels in those with only risk factors of DM at ONH is currently less clear. It was anticipated that the vascular study in individual with only risk factors of DM would identify early changes in retinal vascular network due to metabolic and hemodynamics alteration. Taking the above predicaments together, the main goal of this work, particularly for this last experiment, was to examine the potential use of SAFP for retinal vascular Df analysis in individual with and without DM risk factors at ONH.

- Objective 3: To elucidate the difference of Df between groups with risk and non-risk of DM.
- Research hypothesis: Individual with DM risk factors significantly have higher retinal vascular Df compared to non-risk group.

Studies showed that several cardiovascular risk factors including age and high blood pressure have been independently associated with lower Df measurement among normal population with cardiovascular and ocular risk factors (Cheung et al., 2012; Zhu et al., 2014). Smaller retinal Df have been reported in patients with high myopia and cataract (Cheung et al., 2012). To the best of our knowledge, there is no study has yet examined the influence of DM risk factor on retinal vascular Df. As for that, this study was also aimed;

- Objective 4: To explore the potential association of retinal vascular Df with risk factors of DM.
- Hypothesis: It was expected that DM risk factors were independently associated with retinal Df.